

Historical Note

(Section Editor: G. Eknoyan)

History of vascular access for haemodialysis

Klaus Konner

Medizinische Klinik I, Krankenhaus Köln-Merheim, Köln, Germany

Abstract

The history of vascular access is a history of vascular surgery as well as a history of dialysis therapy. This survey is a personal view on the history of vascular access without the ambition to cover every detail, but with an effort to mention the major steps in a fascinating panorama.

non-toxic heparin. Till 1929, he performed eleven treatments in uraemic patients. He did not continue, however, presumably because of the limited efficacy and the lack of recognition by his peers. He died in 1971 having witnessed the arrival of modern haemodialysis techniques.

How it all started

1896

Jaboulay and Briau (Lyon, France) published an experimental technique in dogs which consisted of suturing an artery-end-to-end-anastomosis. The authors already mentioned technical details proposed again in current literature, e.g. the eversion of the suture, an essential tool against thrombosis (Figure 1) [1]. A few years later, Alexis Carrel, who grew up in Lyon, later moved to Chicago, Baltimore and New York, introduced the three-point end-to-end and a side-to-side-anastomosis, a milestone and still used today (Figure 2) [2]. Carrel was awarded the Nobel Prize in 1912.

1943

Modern haemodialysis therapy started on 17 March 1943, when Willem Kolff, a young doctor in the small hospital of Kampen (The Netherlands), treated a 29-year-old housemaid suffering from malignant hypertension and ‘contracted kidneys’. Kolff had constructed a ‘rotating drum kidney’ with the support of Mr Berk, the director of the local enamel factory. First, Kolff used only venipuncture needles to obtain blood from the femoral artery and to reinfuse it by puncturing a vein. Later, he performed surgical cut-down of the radial artery which caused severe bleeding during heparinization. On 11 September 1945 the first of his 17 patients survived, a 67-year-old woman with cholecystitis and sulphonamide nephrotoxicity. Kolff left the Netherlands in 1950 and continued to work in the field of artificial organs in the USA.

1924

In October 1924, Georg Haas (Giessen, Germany) performed the first haemodialysis treatment in humans which lasted 15 min. He was supported by a grant from the Rockefeller Foundation. He first used glass cannulae to obtain arterial blood from the radial artery, which he returned to the cubital vein. Later he performed a surgical cut-down to place a cannula into the radial artery and into an adjacent vein. As an anticoagulant, he initially used a purified hirudin preparation which nevertheless caused severe reactions so that from 1927 onward hirudin was replaced by the

In the years that followed, substantial technical developments are linked to the names of Nils Alwall in Lund (Sweden) and John P. Merrill in Boston (USA). In the 1950s, the technical devices were available for regular haemodialysis treatments, e.g. Kolff’s so-called twin-coil kidney [3] – but, the Achilles heel was a reliable access to the circulation for multiple use which did not yet exist.

The pioneers of maintenance haemodialysis

1960

In 1949, Alwall tried to use a rubber tubing and glass cannula device to connect artery and vein, but he failed. This idea of Alwall was later taken up by Quinton, Dillard and Scribner (Seattle, USA) who developed an arteriovenous (AV) Teflon shunt [4]. Only 10 weeks

Correspondence and offprint requests to: Klaus Konner, Medizinische Klinik I, Krankenhaus Köln-Merheim, Köln, Germany. Email: klaus.konner@uni-koeln.de

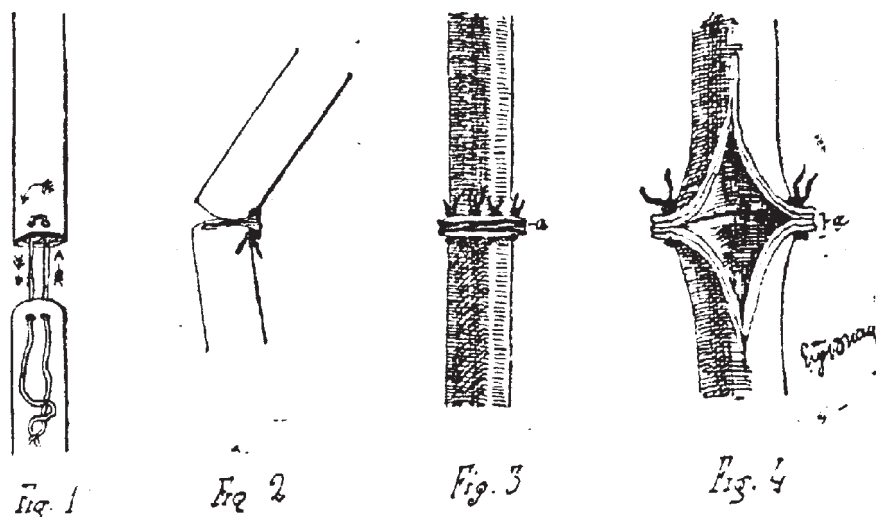


Fig. 1. Animal experiments with vascular anastomoses by Jaboulay and Briau, published 1896 [1].

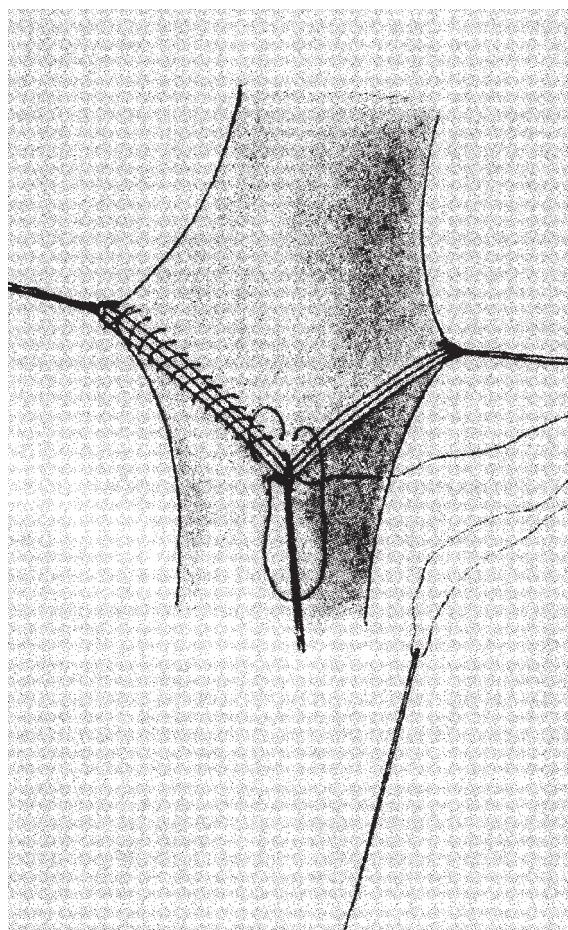


Fig. 2. Three-point-end-to-end anastomosis by Carrel, published 1912 [2].

after the first patient, Clyde Shields, had been taken on maintenance haemodialysis, Scribner published a 'Preliminary report on the treatment of chronic uremia by means of intermittent hemodialysis', which described with clairvoyance some medical problems plaguing renal replacement therapy still today: malnutrition,

hypertension, anaemia and others [5]. Clyde Shields, a Boeing machinist, survived for 11 years after the insertion of his first AV shunt on 9 March 1960. Two thin-walled Teflon cannulas with tapered ends were inserted near the wrist in the forearm, one into the radial artery and the other into the adjacent cephalic vein. The external ends were connected by a curved teflon bypass tube. Later, the Teflon tube was replaced by flexible silicon rubber tubing.

Scribner wrote in 1990: 'Successful treatment of Clyde Shields represents one of the few instances in medicine where a single success was required to validate a new therapy' [6]. The development of a permanent vascular access by the Seattle group was the decisive breakthrough, which made maintenance dialysis possible. It is rightly considered a landmark in the history of dialysis: maintenance haemodialysis therapy began on 9 March 1960. Many variants of the AV shunt came into use during the following years when the majority of AV-shunt insertions concerned temporary vascular access at the start of chronic dialysis therapy to bridge the time when an AV fistula was absent or maturing.

During early 1970s, TJ Buselmeier and co-workers (Minneapolis, USA) developed a compact U-shaped silastic prosthetic AV shunt with either one or two Teflon plugged outlets which communicated to the outside of the body. The U-shaped portion could be totally or partially implanted subcutaneously [7]. This modification of the Scribner AV shunt gained some acceptance during the following years, especially for paediatric haemodialysis patients.

1961

At that time, Stanley Shaldon (London, UK) faced the problem of finding a surgeon willing to operate on the radial artery and cephalic vein to introduce cannulae for circulatory access. To become independent, Shaldon introduced hand-made catheters into the femoral artery and vein by the percutaneous

Seldinger technique for immediate vascular access [8,9]. Over time, vessels in different sites were used, including the subclavian vein. Shaldon concluded: 'Eventually, veno-venous catheterization was preferred because the bleeding from the femoral vein was less than from the femoral artery when the catheter was removed' [10]. Regional heparinization was practised with hexadimethrine bromide ('Polybrene') to neutralize the anticoagulant effect of heparin. Obviously, these catheters are not identical with the widely used type of catheters for temporary access, which today are usually called 'Shaldon catheters'.

1962

James E. Cimino and Michael J. Brescia (New York, USA) described a 'simple venipuncture for hemodialysis' based on the experience of Dr Cimino when he worked part-time as a student at the Bellevue Transfusion Center in New York [11]. After prior infiltration of the overlying skin with 1% procaine, the most accessible forearm vein was punctured with a needle. Needle sizes varied from No. 16 to No. 12 gauge. Patency of the vein and adequate blood supply were assured by application of tourniquet pressure with a sphygmomanometer. A blood flow in the range of 150 and 410 ml/min was obtained in these mainly fluid overloaded patients.

1963

Thomas J. Fogarty from Cincinnati, USA, invented an intravascular catheter with an inflatable balloon at its distal tip designed for embolectomy and thrombectomy – an essential device even today [12].

1966

The legendary paper 'Chronic hemodialysis using venipuncture and a surgically created arteriovenous fistula' was published by Brescia, Cimino, Appell and Hurwich [13]. Dr Appell was the surgeon in the team. The first surgically created fistula for the purpose of haemodialysis was placed on 19 February 1965, followed by further 14 operations as of 21 June 1966. Twelve out of these 14 AV fistulae resumed primary function without complications, two never functioned (in the first patient, the anastomosis 'was made too small'). This represents an early failure rate which would be admirably low even in 2005. Dr Scribner from Seattle was the first nephrologist to refer one of his patients to New York for the creation of an AV fistula.

Dr Appel had performed a side-to-side-anastomosis between the radial artery and the cephalic antebachial vein at the wrist after a 3–5 mm incision had been made in the corresponding lateral surfaces of the artery and the vein. The suture was achieved using arterial silk in continuous fashion.

Many years later, in 1994, Dr Cimino stated that 'the decision to connect an artery and vein subcuta-

neously, thus creating an internal shunt, appeared not only logical but was the classic example of necessity as the mother of invention' and 'that arteriovenous fistulas could lead to heart failure, and this would be particularly hazardous in patients whose cardiovascular systems were already compromised' [14].

Drs Cimino and Appell left the Veterans Administration Hospital, Bronx, New York, a few years later: Dr Cimino is still busy practising palliative medicine at the Calvary Hospital, Bronx, New York; Dr Appell has retired after a successful career as a 'countryside' general surgeon in the greater New York area [Personal communication, April 2005].

1967

One year after the article of Brescia and Cimino, M. Sperling (Würzburg, Germany) reported the successful creation of an end-to-end-anastomosis between the radial artery and the cephalic antebachial vein in the forearm of 15 patients using a stapler [15]. This type of AV anastomosis gained widespread acceptance during the next decade, mainly based on the rationale to restrict the inflow of blood into the AV fistulae to the flow provided by the feeding radial artery. The creation of an end-to-end anastomosis was technically challenging; an additional problem arose because the diameters of artery and vein were different; various patch techniques were tried to solve this problem. Because of the increasing numbers of elderly, hypertensive and diabetic patients with difficult vessels and high risk of a steal syndrome, this type of AV fistula was abandoned as the first vascular access of choice. End-to-end-anastomoses are still a well established technique in revision procedures. The stapler, however, never was accepted as a routine technical tool.

For the transluminal recanalization of arteries obstructed by atherosclerotic plaques Charles T. Dotter and co-workers (Portland, USA) introduced a type of balloon catheter. The first angioplasty represented an essential contribution to resolve one of the great problems in vascular surgery and vascular access surgery [16].

1968

Lars Röhl from Heidelberg, Germany, published his results in 30 radial-artery-side-to-vein-end-anastomoses [17]. After completion of the anastomosis, the radial artery was ligated distal to the anastomosis, thus resulting in a functional end-to-end-anastomosis. With this technique, an antebachial cephalic vein located at a more lateral position which would not have been suitable for a side-to-side-anastomosis, could be used successfully. Later on, the ligation of the peripheral arterial limb only was practised in patients with impending signs of peripheral ischaemia.

Today, the artery-side-to-vein-end-anastomosis has become a standard procedure. The handling of

the 'free end' of the vein should not be underestimated, however. Torsion and kinking of the vessel unfortunately are common errors that predispose to fistula failure.

1969

In 1952, the French anatomist Robert Aubaniac, living in Algeria, had described the puncture of the subclavian vein [18]. After the first use of the subclavian route for haemodialysis access by Shaldon in 1961, this technique was adapted by Josef Erben from the former Czechoslovakia, using the infraclavicular route [19]. In addition, this catheter permitted to control central venous pressure in dehydrated, oliguric haemodialysis patients. During the following two decades the subclavian approach was the preferred route for temporary vascular access by central venous catheterization. Today, time has come to abandon subclavian cannulas in patients with chronic renal disease, since phlebographic studies revealed a 50% stenosis or occlusion rate at the site of cannulation. This predisposes to oedema of the arm, especially after creation of an AV fistula [20].

Based on animal experiments, George I. Thomas from Seattle, USA, presented his 'Dacron applique shunt' in 10 patients [21]. The idea was to eliminate all intraluminal foreign body, thus avoiding any area predisposing to thrombus formation. The author sutured oval Dacron patches to the common femoral artery and the saphenous/common femoral vein. The Dacron patches were connected with silastic tubes and brought to the surface of the anterior thigh approximately 10 cm distal to the femoral wound. In desperate cases, some groups still use the Thomas-shunt [22].

For patients with lack of or exhaustion of peripheral veins, a new idea came up: Gilberto Flores Izquierdo (Mexico City) [23] and James May (Sidney, Australia) [24] proposed to remove the segment of the saphenous vein between groin and knee and to connect it in a U-shaped fashion in the elbow region with the brachial artery and a suitable vein. As a variant it was proposed to implant the totally mobilized vein to the great vessels in the thigh or to anastomose the distally mobilized saphenous vein to the femoral artery. The first step of using a graft in vascular access surgery was done. In 1970, Roland E. Girardet from New York, USA, analysed his results with this novel technique [25].

New ideas

1970

A '16 month's experience with the subcutaneously fixed superficial femoral artery for chronic haemodialysis' was published by W.D. Brittinger (Mannheim, Germany) [26]. Following a femoral arteriogram to exclude arterial anomalies or disease, the superficial

femoral artery was exposed, the musculus sartorius was mobilized. Both ends of the musculus sartorius were passed underneath the exposed artery and joined again. The fascia lata was closed, ensuring that proximal and distal openings of the fascia were sufficiently large to prevent compression of the artery. Seventeen patients had undergone this procedure successfully.

The first clinical results with a mandril graft were reported by Charles H. Sparks (Portland, USA) based on a series of animal experiments starting in 1965 [27]. He implanted a silicone mandril assembly consisting of a silicone rubber rod with a covering of two specially prepared siliconized knitted Dacron tubes. It was left in place for 6 weeks so that the Dacron mesh became organized after invasion of the surrounding tissue. The mandril was then removed and the endings of the matured subcutaneous tunnel were anastomosed to the native vessels. The first report on the use in haemodialysis patients was given by Beemer in 1973 [28]. Because of the unfavourable results and the availability of more successful prosthetic materials this technique was abandoned a few years later.

1971

G. Capodicasa from Naples (Italy) posed the question 'Is a shunt an indispensable requirement for repeated haemodialysis?' and presented his technique of mobilizing and fixing the radial artery underneath the skin throughout its length along the forearm [29], but there were no further publications to confirm the value of this procedure.

The first idea to implant a plastic valve as circulatory access was reported by W.D. Brittinger (Figure 3).

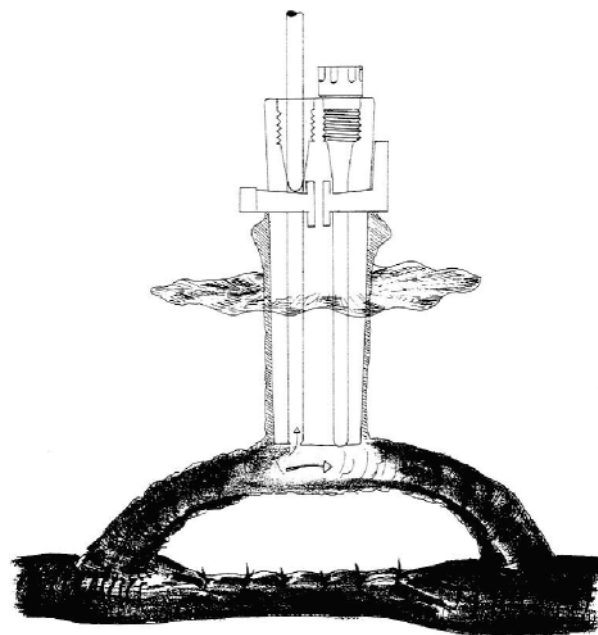


Fig. 3. Plastic valve, experimentally implanted into a femoral artery, published 1971 [31] (courtesy of Prof. W.D. Brittinger, Neckargemünd, Germany).

In an animal model, he inserted a massive silastic cylinder with a Dacron skirt end-to-side into a sheep carotid artery. The implantation of this device into a human superficialized femoral artery was planned, but unfortunately not realized [30].

New types of grafts

1972

The year 1972 saw the introduction of three new graft materials, one biologic and two synthetic.

A modified bovine carotid artery biologic graft (Artegraft, Johnson & Johnson), a product of research by D.M.L. Rosenberg, was introduced for construction of vascular access in eight haemodialysis patients by Joel L. Chinitz [31] (Philadelphia, USA). It was the first xeno-graft and received some acceptance during the 1970s.

T. Soyer (Denver, USA) used expanded polytetrafluoroethylene (ePTFE) in animal experiments to replace various major thoracic and abdominal veins [32]. In 1976, L.D. Baker Jr (Phoenix, USA) presented the first results with expanded PTFE grafts in 72 haemodialysis patients [33]. The majority of these grafts were 8 mm in diameter. Numerous publications during the subsequent years demonstrated the value and the limitations of this prosthetic material, which has remained the first choice of grafts for vascular haemodialysis access even today.

Irving Dunn (Brooklyn, NY, USA) had chosen a dacron velour vascular graft for creation of AV bridge grafts, initially in animal experiments and then in a uraemic female patient [34]. Subsequently, this material did not yield satisfactory results for vascular access, although in other fields of vascular surgery it has become well accepted as graft material.

The fact that Dacron was not accepted and that ePTFE continues to be the material of choice highlights the fact that in the field of vascular access special criteria must be met by the graft material: apart from safety and ease of handling during the operation, in addition, no formation of aneurysms after repeated cannulation and low infection rates are required; easy surgical replacement of graft segments in cases of infected and aneurysmatic grafts is another important prerequisite.

1973

T.W. Staple (St Louis, USA) described a novel angiographic technique in his paper 'Retrograde venography of subcutaneous arteriovenous fistulas created surgically for hemodialysis' [35]. During subsequent years, further substantial contributions came from the St Louis group with Louis A. Gilula, the radiologist, and Charles B. Anderson, the vascular surgeon. This angiographic technique is still used today, preferably in combination with the digital subtraction device. M. Thelen (Bonn, Germany)

had already published this 'retrograde venography' technique in AV shunts and fistulas 1 year before in a German radiologic journal [36].

Andreas Grüntzig from Zürich, Switzerland, continued the work of Dotter using the then new catheter technique to recanalize chronic arterial occlusions, the basis of modern angioplasty [37].

1976

Two authors had worked for a few years with a new graft material: the human umbilical cord vein because of the perceived advantages of an antithrombogenic intimal inner surface and the absence of valves and branches. B.P. Mindich (New York) used chemically processed umbilical cord veins without external support, whereas H. Dardik (New York) surrounded the graft with a polyester fibre mesh [38,39]. This material never achieved a real breakthrough because of insufficient resistance against the trauma of repeated cannulation and of problematic surgical revision in the case of aneurysm and infection.

1977

A group from Chicago with Dr Gracz as first author published an article on 'Proximal forearm fistula for maintenance hemodialysis', a variant of an AV anastomosis. They sutured the perforating vein to the proximal radial, ulnar or brachial artery [40]. Recently, a modification of this type of AV fistula gained some importance as a vascular access in the old, hypertensive and diabetic patients because it permits a proximal anastomosis with a low risk of hypercirculation, as blood flow is limited by the finite diameter of the perforating vein (3–5 mm) [41].

1979

A.L. Golding and co-workers (Los Angeles, USA) developed a 'carbon transcatheter hemodialysis access device' (CATD), commonly known as 'button', as a blood access not requiring needle puncture [42]. The device consisted of two components: a vitreous carbon access port sealed with a conical polyethylene plug and a PTFE graft securely and smoothly attached to the port. It could easily be connected with specially constructed bloodlines. As a procedure of third choice, these devices were expensive and never gained widespread acceptance.

F.L. Shapiro (Minneapolis, USA) described another type of 'button', a device similar to that developed by Golding [43]. In 1983, J.L. Wellington (Ottawa, Canada) tried to implant these buttons along an arterialized, superficialized basilic vein – a promising idea, but the results were disappointing [Personal communication, 1983]. Because only few groups used these devices, the experience remained limited.

A remarkable publication came from Joseph L. Giacchino (Maywood, USA) discussing uncommon

techniques like the reverse AV fistula, unusually located interposition grafts and brachio-brachial arterio-arterialgrafts [44].

The first report on a new angiographic technique, known as digital subtraction angiography was published by David L. Ergun (Madison, USA): 'A hybrid computerized fluoroscopy technique for noninvasive cardiovascular imaging'. Later, this technique was adapted to visualize AV fistulas and prosthetic bridge grafts, using the arterial as well as the venous route [45].

Recent ideas

1980–1992

A highly informative paper was published by W.P. Geis, together with Dr Giacchino: 'A game plan for vascular access for hemodialysis' – a collection of innovative, creative ideas concerning arteriovenous fistulas as well as graft insertion in various locations [46].

The era of the percutaneous, transluminal angioplasty in vascular accesses started with a publication of David H. Gordon and Sidney Glanz (New York, USA) based on the work of Grüntzig: 'Treatment of stenotic lesions in dialysis access fistulas and shunts by transluminal angioplasty' [47].

G. Krönung (Bonn, Germany) published fundamental ideas on how different types of cannulation affected the remodelling of the venous arm of the fistula [48]. He demonstrated that cannulation may not only destroy the vein, but is essential for remodelling. Thus, cannulation can be an effective tool to avoid the formation of aneurysms and stenoses.

In patients with exhausted vessel anatomy in both arms or stenoses along the subclavian vein resistant to intervention José R. Polo (Madrid, Spain) introduced the concept of 'brachial-jugular polytetrafluoroethylene fistulas for hemodialysis' [49], a brilliant solution for the occasional patient who may profit from creation of a graft-vein-anastomosis using the internal jugular vein.

While angiographic and interventional radiologic techniques became widely accepted, non-invasive ultrasound techniques, mainly used by nephrologists, were introduced only slowly. A landmark was the article of Barbara Nonnast-Daniel (Hannover, Germany) on 'Colour doppler ultrasound assessment of arteriovenous haemodialysis fistulas' [50]. She was able to obtain anatomic and functional parameters, which were useful to guide the surgeon for optimizing the procedure in the first access operation, but also useful for surveillance and monitoring the function of the access during follow-up.

Outlook

The above remarks reflect the subjective assessment of what we consider are the highlights in past efforts to

optimize the vascular access in haemodialysis patients. Knowledge of these ingenious, innovative, sometimes even bold ideas, although not always successful, is stimulating and hopefully also useful to the physician struggling with the challenge to construct vascular accesses nowadays. Creative efforts provided a variety of solutions in the past and so, we are happy today to play on more than one instrument.

Vascular access surgery has become an interdisciplinary field of modern medicine. Once it had been inaugurated by pioneers in nephrology at a time when access surgery was unknown in the then still young discipline of vascular surgery. In the early 1970s, with the increasing complexity of access related problems, nephrologists delegated the responsibility for the vascular access more and more to their surgeons. For many years, vascular access was regarded as an exclusively surgical problem. With the introduction of non-invasive preoperative mapping of blood vessels, of earlier referral to nephrologists and to access surgeons and of venous preservation, nephrologists must learn again to assume responsibility for vascular access. Beyond the preservation of vessels in the predialytic phase, this includes surveillance and monitoring of the established access, but also acquiring up-to-date knowledge on the surgical options and many other aspects, but above all maintaining close cooperation with surgeons and radiologists.

What is required today is a completely new approach to comprehensive access management that has to escape from crisis management. History may be helpful.

Acknowledgements. I am indebted to Prof. Eberhard Ritz, Heidelberg, Germany for insightful comments and review of the manuscript. Thanks also to Dr Dirk Hentschel, Harvard Medical School, Boston, USA for providing the author with Figures 1 and 2.

Conflict of interest statement. None declared.

References

1. Jaboulay M, Briau E. Recherches expérimentelles sur la suture et la greffe artérielles. *Lyon Méd* 1896; 81: 97–99
2. Carrel A. Technique and remote results of vascular anastomoses. *Surg Gynecol Obstet* 1912; 14: 246–254
3. Kolff WJ. First clinical experience with the artificial kidney. *Ann Int Med* 1965; 62: 608–619
4. Quinton WE, Dillard DH, Scribner BH. Cannulation of blood vessels for prolonged hemodialysis. *Trans Am Soc Artif Intern Organs* 1960; 6: 104–113
5. Scribner BH, Buri R, Caner JEZ, Hegstom R, Burnell JM. The treatment of chronic uremia by means of intermittent hemodialysis: a preliminary report. *Trans Am Soc Artif Intern Organs* 1960; 6: 114–122
6. Scribner BH. A personalized history of chronic hemodialysis. *Am J Kidney Dis* 1990; 16: 511–519
7. Buselmeier TJ, Kjellstrand CM, Simmons RL *et al.* A totally new subcutaneous prosthetic arterio-venous shunt. *Trans Am Soc Internal Artif Organs* 1973; 19: 25–32
8. Seldinger SI. Catheter replacement of the needle in percutaneous arteriography: a new technique. *Acta Radiol* 1953; 39: 368–376

9. Shaldon S, Chiandussi L, Higgs B. Haemodialysis by percutaneous catheterization of the femoral artery and vein with regional heparinization. *Lancet* 1961; II: 857–859
10. Shaldon S. Percutaneous vessel catheterization for hemodialysis. *ASAIO J* 1994; 40: 17–19
11. Cimino JE, Brescia MJ. Simple venipuncture for hemodialysis. *N Engl J Med* 1962; 267: 608–609
12. Fogarty TJ, Cranley JJ, Krause RJ, Strasser ES, Hafner CD. A method for extraction of arterial emboli and thrombi. *Surg Gynecol Obstet* 1963; 116: 241
13. Brescia MJ, Cimino JE, Appel K, Hurwicz BJ. Chronic hemodialysis using venipuncture and a surgically created arteriovenous fistula. *N Engl J Med* 1966; 275: 1089–1092
14. Cimino JE, Brescia MJ. The early development of the arteriovenous fistula needle technique for hemodialysis. *ASAIO J* 1994; 40: 923–927
15. Sperling M, Kleinschmidt W, Wilhelm A, Heidland A, Klütsch K. Die subkutane arteriovenöse Fistel zur intermittierenden Hämodialyse-Behandlung. *Dtsch Med Wschr* 1967; 92: 425–426
16. Dotter CT, Judkins MP, Rösch J. Nonoperative treatment of arterial occlusive disease. A radiologically facilitated technique. *Radiol Clin N Am* 1967; 5: 531–542
17. Röhl L, Franz HE, Möhring K *et al*. Direct arteriovenous fistula for hemodialysis. *Scand J Urol Nephrol* 1968; 2: 191–195
18. Aubaniac R. Une nouvelle voie d'injection ou de ponction veineuse: la voie sous-claviculaire. *Sem Hop Paris* 1952; 28: 3445–3447
19. Erben J, Kvasnicka J, Bastecky J, Vortel V. Experience with routine use of subclavian vein cannulation in haemodialysis. *Proc EDTA* 1969; 6: 59–64
20. Schillinger F, Schillinger D, Montagnac R, Milcent T. Post catheterization vein stenosis in haemodialysis: comparative angiographic study of 50 subclavian and 50 internal jugular accesses. *Nephrol Dial Transplant* 1991; 6: 722–724
21. Thomas GI. A large vessel applique A-V-shunt for hemodialysis. *Trans Am Soc Artif Intern Organs* 1969; 15: 288–292
22. Coronel F, Herrero JA, Mateos P, Illescas ML, Torrente J, del Valle MJ. Long-term experience with the Thomas shunt, the forgotten permanent vascular access for haemodialysis. *Nephrol Dial Transplant* 2001; 16: 1845–1849
23. Flores-Izquierdo G, Vivero RR, Exaire E, Chavez AH, de los Rios JG. Autoinjerto venoso para hemodialysis (Tecnica original). *Arch Inst Cardiol Mex* 1969; 39: 259–266
24. May J, Tiller D, Johnson J, Stewart J, Sheil AGR. Saphenous-vein arteriovenous fistula in regular dialysis treatment. *N Engl J Med* 1969; 280: 770
25. Girardet RE, Hackett RE, Goodwin NJ, Friedman EA. Thirteen months experience with the saphenous vein graft arteriovenous fistula for maintenance hemodialysis. *Trans Am Soc Artif Intern Organs* 1970; 16: 285–291
26. Brittinger WD, Strauch M, Huber W *et al*. 16 months experience with the subcutaneously fixed superficial femoral artery for chronic haemodialysis. *Proc EDTA* 1970; 7: 408–412
27. Sparks CH. Die-grown reinforced arterial grafts: observations on long-term animal grafts and clinical experience. *Ann Surg* 1970; 172: 787–794
28. Beemer RK, Hayes J. Hemodialysis using a mandril-grown graft. *Trans Am Soc Artif Intern Organs* 1973; 19: 43–48
29. Capodicasa G, Perna N, Giordano C. Is a shunt an indispensable requirement for repeated haemodialysis? *Proc EDTA* 1971; 8: 517–520
30. Brittinger W-D, von Henning GE, Twittenhoff W-D *et al*. Implantation of a plastic valve into the superficialised femoral artery. *Proc EDTA* 1971; 8: 521–525
31. Chinitz JL, Yokoyama T, Bower R, Swartz C. Self-sealing prosthesis for arteriovenous fistula in man. *Trans Am Soc Artif Intern Organs* 1972; 18: 452–455
32. Soyer T, Lempinen M, Cooper P, Norton L, Eiseman B. A new venous prosthesis. *Surgery* 1972; 72: 864–872
33. Baker LD Jr, Johnson JM, Goldfarb D. Expanded polytetrafluoroethylene (PTFE) subcutaneous arteriovenous conduit: an improved vascular access for chronic hemodialysis. *Trans Am Soc Artif Intern Organs* 1976; 22: 382–387
34. Dunn I, Frumkin E, Forte R, Raquena R, Levowitz BS. Dacron velour vascular prosthesis for hemodialysis. *Proc Clin Dial Transplant Forum* 1972; 2: 85
35. Staple TW. Retrograde venography of subcutaneous arteriovenous fistulas created surgically for hemodialysis. *Radiology* 1973; 106: 223–224
36. Thelen M, Frotscher U, Frommhold H, Kozuschek W. Angiographische Darstellung von arteriovenösen Shunts bei Dialysepatienten. *Fortschr Roentgenstr* 1972; 117: 438–444
37. Grüntzig A, Bollinger A, Brunner U, Schlumpf M, Wellauer J. Perkutane Rekanalisation chronischer arterieller Verschlüsse nach Dotter — eine nicht-operative Kathetertechnik. *Schweiz Med Wschr* 1973; 103: 825–831
38. Mindich BP, Levowitz BS. Human umbilical cord vein fistula. A novel approach for hemodialysis. *Dial Transplant* 1976; 5: 19–87
39. Dardik H, Ibrahim IM, Dardik I. Arteriovenous fistulas constructed with modified human umbilical cord vein graft. *Arch Surg* 1976; 111: 60–62
40. Gracz KC, Ing TS, Soung L-S, Armbruster KFW, Seim SK, Merkel FK. Proximal forearm fistula for maintenance hemodialysis. *Kidney Int* 1977; 11: 71–74
41. Konner K. Primary vascular access in diabetic patients: an audit. *Nephrol Dial Transplant* 2000; 15: 1317–1325
42. Golding AL, Nissenson AR, Raible D. Carbon transcatheter access device (CTAD). *Proc Dial Transplant Forum* 1979; 9: 242–247
43. Shapiro FL, Keshaviah P, Carlson LD *et al*. Blood access without percutaneous punctures. *Proc Dial Transplant Forum* 1980; 10: 130–137
44. Giacchino JL, Geis WP, Buckingham JM, Vertuno LL, Bansal VK. Vascular access: long-term results, new techniques. *Arch Surg* 1979; 114: 403–409
45. Ergun DL, Mistretta CA, Kruger RA, Riederer SJ, Shaw CG, Carbone DP. A hybrid computerized fluoroscopy technique for noninvasive cardiovascular imaging. *Radiology* 1979; 132: 739–742
46. Geis WP, Giacchino JL. A game plan for vascular access for hemodialysis. *Surg Rounds* 1980; 62–70
47. Gordon DH, Glanz S, Butt KMH, Adamsons RJ, Koenig MA. Treatment of stenotic lesions in dialysis access fistulas and shunts by transluminal angioplasty. *Radiology* 1982; 143: 53–58
48. Krönung G. Plastic deformation of Cimino fistula by repeated puncture. *Dial Transplant* 1984; 13: 635–638
49. Polo JR, Sanabia J, Garcia-Sabrido JL, Luno J, Menarguez C, Echenagusia A. Brachial-jugular polytetrafluoroethylene fistulas for hemodialysis. *Am J Kidney Dis* 1990; 16: 465–468
50. Nonnast-Daniel B, Martin RP, Lindert O *et al*. Colour doppler ultrasound assessment of arteriovenous haemodialysis fistulas. *Lancet* 1992; 339: 143–145